



SJS

SRIWIJAYA JOURNAL OF SURGERY

Sriwijaya Journal of Surgery Volume 3, Issue 2, Page No: 88-95

Available online: www.sriwijayasurgery.com

SJS 3(2): 88-95

Comparison of Scar Modified Radical Mastectomy Surgery Using Songket Technique and Standard Technique in Dr. Mohammad Hoesin General Hospital in Palembang

Rangga Kusuma Maulana¹, Iqmal Perlianta^{1*}, Mufida Muzakkie¹, Nur Qodir¹, Erial Bahar¹

¹Department of Surgery, Faculty of Medicine, Universitas Sriwijaya, Palembang, Indonesia

*Correspondence Author Email: iqmal.perlianta@gmail.com

Abstract


Introduction: Lateral ear dogs and loss of anterior axillary fold are side effects of modified radical mastectomy (MRM) operations and are cosmetically unpleasant. Songket technique is expected to reduce the side effects of MRM surgery. This study compared the Modified Radical Mastectomy surgery scar using Songket and standard techniques.

Methods: This research is a clinical randomized trial. With anterior chest thoracic data of postoperative patients and assessed by the patient's family and medical professionals using a likert scale on wound length, wound width, wound angle and armpit folding. This study was performed in the Department of Surgery Mohammad Hoesin Hospital Palembang from January 2020 to April 2020.

Results: A total of 32 research subjects participated with the average Likert scale score on medical and family assessments between the Songket and standard technique groups with p values of 0.605 and 0.984, respectively.

Conclusion: There was no difference in comparison of scar Modified Radical Mastectomy operations using Songket techniques and standard techniques at Mohammad Hoesin Hospital in Palembang.

Keyword: modified radical mastectomy, breast cancer, plastic surgery.



1. Introduction

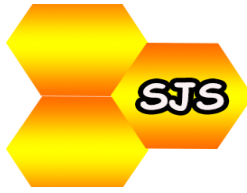Breast cancer is the most common cancer in women worldwide, with an estimated 1.67 million new cases in 2012.¹ *Modified Radical Mastectomy* (MRM) is the most commonly performed surgery for breast cancer. However, if the MRM incision is not well planned, it can cause lateral ear dogs and loss of the anterior axillary fold.^{2,3} This is not only cosmetically unpleasant but also causes discomfort in the patient and impedes the range of motion of the arm. The formation of lateral ear dogs after MRM is commonly conducted in obese patients. While the loss of anterior axillary fold almost always occurs due to axilla KGB dissection

Lateral ear dog post-MRM and loss of anterior axillary fold are not only a cosmetic failure but also a source of discomfort in patients. The actual number of incidents is unclear but is a problem most often complained of in post-mastectomy patients.⁴⁻⁶

The standard operating technique used at Mohammad Hoesin Hospital is using a Stewart incision design with an axis on the thorax midlevel and a semi-elliptical form of excision. Furthermore, the design of this incision has the advantage of being easy to do but has the disadvantage of difficult axilla access, surgical scars, and loss of axillary fold and results in persistent folds of skin at the lateral end of the scar, giving the shape of ear dogs and disruption to the movement of the hands in the injured area.⁷

At Mohammad Hoesin Hospital Palembang (RSMH), an MRM operation technique called the Songket technique was created which consisted of a crescent incision design, axillary anchor with a buried mixed mattress suture and rule of the half. This technique has more comprehensive exposure advantages with better surgical scars. It is hoped that this technique can reduce the side effects of standard, modified radical mastectomy surgery techniques used in Palembang's Mohammad Hoesin Hospital.

Based on the above background, the researcher wanted to make a comparison of the Modified Radical Mastectomy scar operation using the Songket technique and standard techniques at Mohammad Hoesin Hospital in Palembang.



2. Method

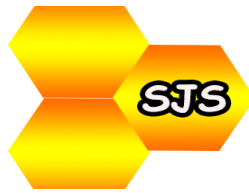This study was used clinical randomized trial design. By collecting data that is an anterior chest thoracic postoperative patient. The patient's family, patients and medical professionals will assess all photos using a Likert Scale. The study population was breast cancer patients who performed modified radical mastectomy (MRM) at Muhammad Hosein Hospital in Palembang. The sample was breast cancer patients who performed MRM at Palembang Hosein Hospital that met the inclusion criteria. In this study, the sample size was determined through a statistical approach. The independent variable was assessed as a photograph of a wound from a Modified Radical Mastectomy surgery. The dependent variable is the assessment of medical professionals using Likert scoring.

Inclusion criteria are patients with a diagnosis of breast cancer. Breast cancer is managed by MRM surgery. Willing to participate in research and sign informed consent. Exclusion criteria were that after MRM, the wound could not be closed or treated openly.

The study was conducted in the Department of Surgery of RSMH Palembang. The research starts by proposing until it finished in January 2020 to April 2020. Sampling was done by consecutive sampling according to the inclusion and exclusion criteria. The sample will then be grouped into two groups, namely the MRM Songket technique group and the standard MRM technique at Muhammad Hosein Hospital Palembang. Sample characteristics are presented in tabular form and narration. Data will be analyzed with SPSS, and significance was determined based on $p < 0.05$.

3. Results

This research was conducted in the surgical division of the plastic surgery and reconstruction and oncology surgery department of Palembang RSMH with a sample of breast cancer patients who performed MRM at Palembang RSMH that met the inclusion and exclusion criteria from January 2020 to April 2020. A total of 32 research subjects met the criteria inclusion and exclusion. Characteristics of patients can be seen in Table 1.

**Table 1.** Characteristics of Subject

Variables	Mean \pm SD	Min-Max
Age	48.09 \pm 12.499	27.00 – 87.00
Drain volume	103.75 \pm 125.18	20.00 – 510.00
Length of stay	3.47 \pm 0.72	3.00 – 5.00
Tumour volume	637.34 \pm 273.03	150.00 – 1350.00
Tumour mass	605.28 \pm 280.75	95.00 – 1285.00
BMI	23.3456 \pm 2.56	18.00 – 30.60
Wound length	21.40 \pm 2.60	17.00 – 27.00
Wound width	5.06 \pm 4.68	2.00 – 22.00

The age distribution of research subjects to the Modified Radical Mastectomy technique can be seen in Table 2. The age distribution of research subjects to the Modified Radical Mastectomy technique is that the mean age of the subjects with the Songket technique is 48.32 \pm 14.61 with a median of 46.00 with a minimum age of 27 years and a maximum age of 87 years, while the mean age in subjects with standard techniques was 47.77 \pm 9.12.

Drain volume distribution of research subjects to the Modified Radical Mastectomy technique can be seen in Table 2. Distribution of drain volume of research subjects to the Modified Radical Mastectomy technique there is an average drain volume on subjects with Songket technique is 119.21 \pm 148.42 mL with a median of 60.00 mL with a minimum of 20.00 mL and a maximum 510.00 mL. In comparison, the mean drain volume on subjects with standard techniques was 81.15 \pm 80.67 ML.

The distribution of the duration of treatment of research subjects to the Modified Radical Mastectomy technique can be seen in Table 2. The average length of treatment on subjects with Songket technique is 3.57 \pm 0.76 days with a median of 3.00 days with a minimum of 3.00 days and a maximum of 5.00 days, while the average length of treatment on subjects with standard techniques is 3.30 \pm 0.63.



Tumour volume distribution of research subjects to the Modified Radical Mastectomy technique can be seen in Table 2 distribution of tumour volume in research subjects to the Modified Radical Mastectomy technique. , while the mean age in subjects with standard techniques was 565.38 ± 186.39 .

Tabel 2. Variable Study of Subject

Variable	Songket technique	Standard	P value
Age (Mean \pm SD)	48.32	14.61	0.906
Drain volume (Mean \pm SD)	119.21	148.42	0.603
Length of stay (Mean \pm SD)	3.57	0.76	0.362
Tumour Volume (Mean \pm SD)	686.57	314.52	0.094

4. Discussion

The use of drainage has become a common surgical practice to eliminate the space created during surgery. Drainage is used both prophylactically and therapeutically. The most common use is postoperative prophylaxis to prevent fluid accumulation, e.g. blood or pus. Various types of surgical drainage are used after procedures on the thyroid, breast, axillary and abdominal areas, joint replacement, amputation, and external fixation. Drainage can be classified as active or passive drainage.^{8,9}

Kopelman et al. recommend that drainage can be removed if the drainage volume in the first three days postoperatively is less than 20 ml because keeping them longer inside does not protect against seroma formation. Gupta et al. in a prospectively randomized study grouping patients into drainage five days and eight days after MRM and showing that removal of drainage on the fifth postoperative day was safe but was associated with an increased incidence of aspiration and seroma volume. Dalberg et al. in a large and multicenter Swedish multicenter trial showing that early drainage removal shortens hospital stays without a high risk of seroma formation and other wound complications.^{10,11,12}

The duration of treatment in patients with Modified Radical Mastectomy is determined by several factors, one of which is seroma. Seroma is the most common problem after mastectomy, and most surgeons see it as necessary rather than dangerous complications because it can usually be resolved within a few weeks. However, the excessive fluid buildup will stretch the skin and cause it to become loose, resulting in patient discomfort and extended hospital stays. Research conducted by Guneri found that there was no difference in length of treatment between groups with Modified Radical Mastectomy using a single drain and using a double drain with a value of $p = 0.819$.^{13,14,15}

The surgical approach to breast cancer has changed dramatically in the last 20 years. The goal of breast cancer surgery is to remove the tumour, ensure negative margins and excellent cosmetic results, and protect the breast if possible. Breast magnetic resonance imaging has become a vital imaging tool before surgery, diagnosing additional tumours and assessing tumour area. Tumour to breast volume ratio is an essential predictor of breast conservation and can be measured by MRI and can change medical decisions. The ratio of tumour volume to breast correlates with the type of surgery. As measured on MRI, this ratio is an accurate way to determine the type of surgery that is most suitable for individual patients. It is recommended that the ratio of tumour volume to the breast determined by MRI become part of the surgical planning protocol for patients diagnosed with breast cancer.^{16,17,18}

It is known that there are differences in mean length of injury in the study subjects between groups with a value of $p = 0.03$. However, when analyzed using a Likert scale, there is no difference in the average score of Likert scale for wound length in medical or family assessments between the Songket technique group and the standard technique with a p-value 0.605 and 0.984, respectively. However, if seen descriptively, Songket technique has a mean length score for wound length that is smaller than the average score for standard techniques, i.e. 3.60 ± 0.48 and 3.70 ± 0.57 on a medical assessment. In this study, it was also found that there was no significant difference in mean wound width between the group Songket technique and the standard technique. However, descriptively the Songket technique had a shorter width than the standard technique of 3.52 ± 0.69 and 7.30 ± 6.84 cm. On the Likert scale assessment, it was also found that there was no difference in the average Likert scale for width, but the wound width of the Songket technique was judged to be greater than the standard technique, i.e. 3.81 ± 0.42 and 3.76 ± 0.56 in the medical


assessment. At the angle of the wound and armpit wound under the Likert scale, it is known that there is no difference in the average Likert scale for these parameters between groups. On the descriptive assessment, the Likert scale for the angle of the wound and the armpit fold with the Songket technique is greater than the standard technique.^{19,20,21}

5. Conclusion

There was no significant difference in the comparison of Modified Radical Mastectomy scar operations using Songket techniques and standard techniques at Mohammad Hoesin Hospital in Palembang.

6. References

1. Sobri FB, Azhar Y, Wibisana IGNG, Rachman A. Manajemen Terkini Kanker Payudara Edisi II, Jakarta: Sagung Seto; 2018. hal 218.
2. Globacan. Section of Cancer Surveillance. 2012
3. Suyatno, Emir TP. Bedah Onkologi Diagnosis dan Terapi. Edisi ke-2. Sagung Seto. Jakarta, Indonesia. 2014
4. Data Instalasi Bedah Sentral RS Mohammad Hoesin Palembang 2018.
5. Spear SL. Surgery of The Breast, Principles and Art, Second edition. Willey SC, Robb GL, Hammond DC. Nahabedian MY. Philadelphia: Lippincot Williams & Wilkins; 2006. hal 130.
6. Kocan S, Gursoy A. Body Image of Women With Breast Cancer after Mastectomy: A Qualitative Research. Journal Breast Health. 2016; 12: 145-50
7. Rahmita. Perbandingan Efektivitas Penutupan Luka Mastektomi Metode Eksklusi Aksilla dan Konvensional pada Penderita Karsinoma Payudara di Rumah Sakit Mohammad Hoesin Palembang. Dipublikasikan berupa presentasi podium pada Muktamar Ahli Bedah Indonesia ke-20. Surabaya, 20 Agustus 2015.
8. Jatoi I, Kauffmann M, Petit JY. Atlas of Breast Surgery. Edisi ke-1. Germany. Springer; 2006.
9. Kumar V, Abbas AK, Aster JC. Robbins and Cotran: Pathologic Basis of Disease. Edisi ke-9. Philadelphia. Elsevier: 2015.



10. Spear SL (Ed). *Surgery of The Breast: Principle and Art*. Edisi ke-3. Philadelphia. Lippincot Williams and Wilkins: 2011.
11. Perhimpunan Ahli Bedah Onkologi Indonesia. *Protokol Penatalaksanaan Kanker Payudara*. Jakarta; 2003.
12. Pusat Data dan Informasi Kementrian Kesehatan Republik Indonesia. *Kanker Payudara*. Jakarta: Kementrian Kesehatan Republik Indonesia; 2016.
13. Suryamanggala, YAL. *Gambaran Penderita Kanker Payudara Usia Muda di RSUP Dr. Moehammad Hoesin Palembang*. Dipublikasikan berupa poster pada Mukktamar Ahli Bedah Indonesia ke-20. Surabaya, 20 Agustus 2015.
14. Skandalakis JE. *Skandalakis' Surgical Anatomy*. New York. The McGraw Hill: 2007.
15. Brunicaardi FC (Ed). *Schwartz's Principles of Surgery*. Edisi ke-9. New York. The McGraw Hill: 2010.
16. Conzen SD dkk. *Devita, Hellman & Rosenberg's Cancer: Principles & Practice of Oncology*. Edisi ke-8. Philadelphia: Lippincott Williams & Wilkins; 2008.
17. Jabir MA, Taha A, Shehata MR, Sayed MM, Yehia A. *Post-mastectomy Seroma : Does Dead Space Obliteration Have a Protective Effect?* *Breast Can Curr Res* 2017, 3 : 1- 6.
18. Vitug AF, Newman LA. *Complications in Breast Surgery*. *Surg Clin N Am* 87 (2007) 431-451.
19. Kuroi K, Shimozuma K, Taguchi T, Imai H, Yamashiro H, Ohsumi S et al. *Evidence-Based Risk Factors for Seroma Formation in Breast Surgery*. *Jpn J Clin Oncol* 2006; 36 (4) 197 – 206.
20. Budd DC, Cochran RC, Sturtz DL, Fouty WJ. *Surgical Morbidity After Mastectomy Operation*. *Am J Surg* 1978, 135: 218 – 220
21. Aitkin DR, Minton JP: *Complication Associated with Mastectomy*. *Surg clin North Am* 1983, 63: 1331 – 1351