



**SJS**

**SRIWIJAYA JOURNAL OF SURGERY**

Sriwijaya Journal of Surgery Volume 3, Issue 2, Page No: 66-73

Available online: [www.sriwijayasurgery.com](http://www.sriwijayasurgery.com)

SJS 3(2) : 66-73

**Experience in using Total Elbow Arthroplasty at Dr. Mohammad Hoesin General Hospital  
Palembang  
(Case Series)**

Nur Rachmat Lubis<sup>1\*</sup>, Hendy Rachmat Primana Lubis<sup>1</sup>

<sup>1</sup>Staff Of Orthopaedic and Traumatology, Department of Surgery, Faculty of Medicine, Universitas Sriwijaya/ Dr. Mohammad Hoesin General Hospital, Palembang, Indonesia

<sup>1</sup>Resident Of Orthopaedic and Traumatology Department, Faculty of Medicine, Universitas Padjadjaran/ Dr. Hasan Sadikin General Hospital, Bandung, Indonesia

Corresponding author : [noerrl2@yahoo.com.sg](mailto:noerrl2@yahoo.com.sg)

**Abstract**

Total elbow arthroplasty (TEA) has proven to be a reliable joint replacement procedure that has a high degree of patient satisfaction. Despite these favorable outcomes, few patients with disabling elbow degenerative conditions have TEA recommended to them as an alternative procedure by rheumatologists, physiatrists, or orthopedists.

The semi-constrained, hinged (linked) prosthesis is the most commonly used prosthesis. This prosthesis is stable postoperatively. Patients are encouraged to do range of motion exercises and use their elbow for activities of daily living as dictated by their pain level and status of wound healing. Wound management is critical following TEA.

A posterior triceps-sparing approach, which preserves the continuity of the triceps, when possible, is typically used. Postoperatively the therapist and patient need to respect the integrity of the triceps and posterior incision when performing both active and passive elbow flexion exercises and

functional activities. The surgeon may choose to limit flexion range of motion based on the intraoperative inspection of the triceps tendon.

We have study on 5 cases patients with elbow arthrosis and went TEA for management of elbow pain and joint limitation of movement.

**Keywords:** total elbow arthroplasty (TEA), rheumatologists, physiatrists, orthopaedic

## 1. Introduction

- Total elbow arthroplasty (TEA) has proven to be a reliable joint replacement procedure.
- elbow degenerative conditions have TEA recommended.
- The semi-constrained, hinged (linked) prosthesis is the most commonly used prosthesis.
- This prosthesis is stable postoperatively.

We will explain about the experiences in using Total Elbow Arthroplasty (TEA) at DR. M. Hoesin General Hospital Palembang are as follows.

### Cases

1. Male, 23 years old
2. Male, 42 years old.
3. Female, 47 years old
4. Female, 64 years old
5. Female, 66 years old

### Case 1

Male, 23 years old,

Patient has been unable and difficult to move his right elbow, fixed on 25 degree of flexion. his history of falling and hiting hard object and do traditional treatment since 6 years ago

General conditions :

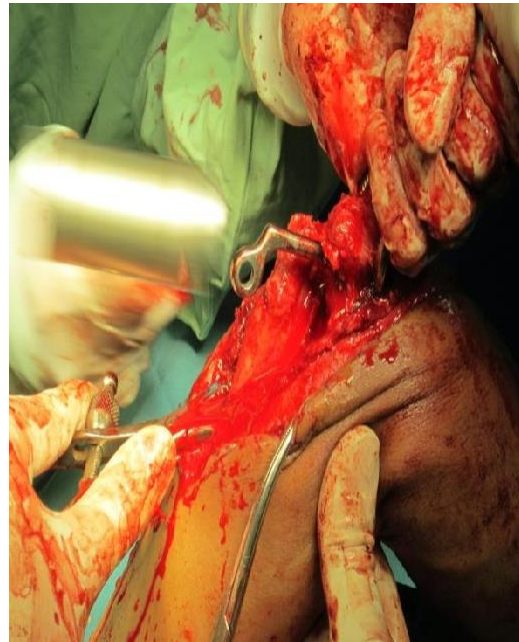
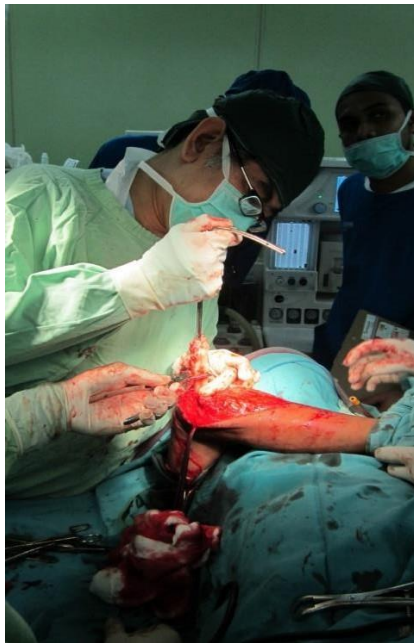
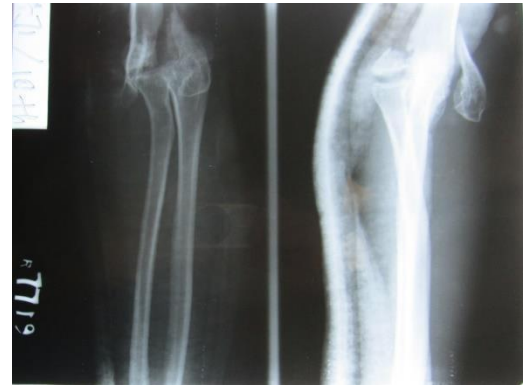
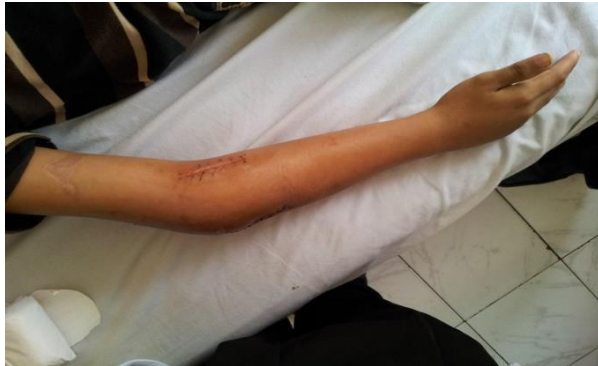- ✓ RR : 20 x/minute

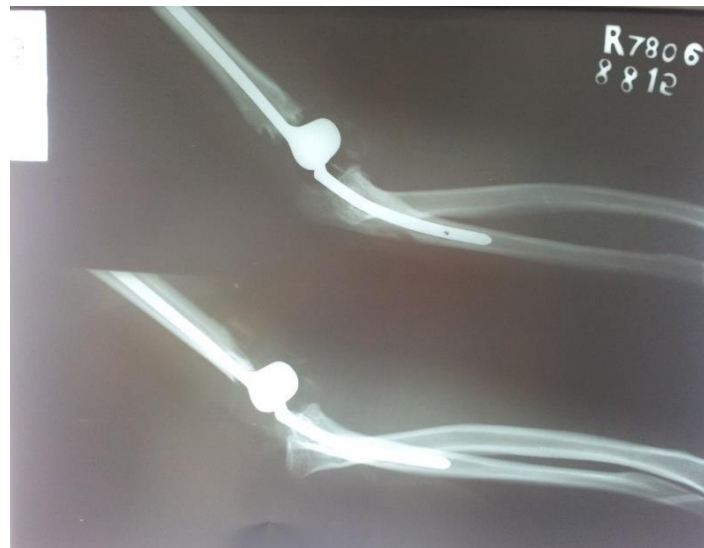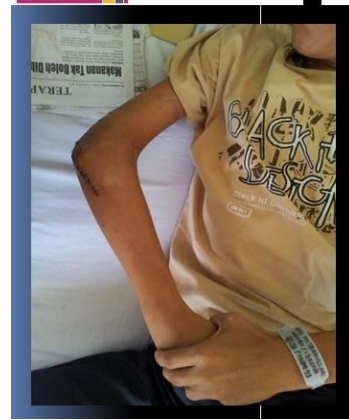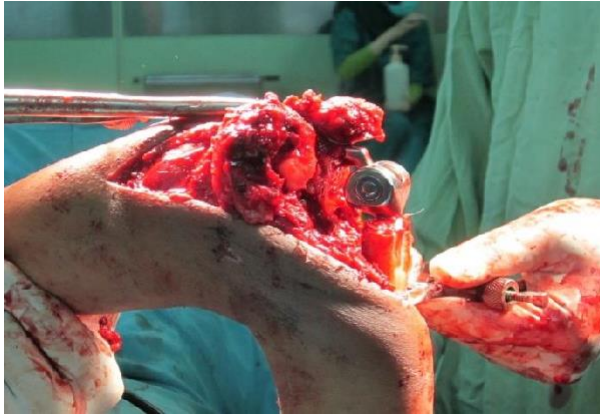


**SJS**

**SRIWIJAYA JOURNAL OF SURGERY**

- ✓ HR : 110/70 mmHg
- ✓ PR : 88 x/minute
- ✓ Temp : 36.8 °C



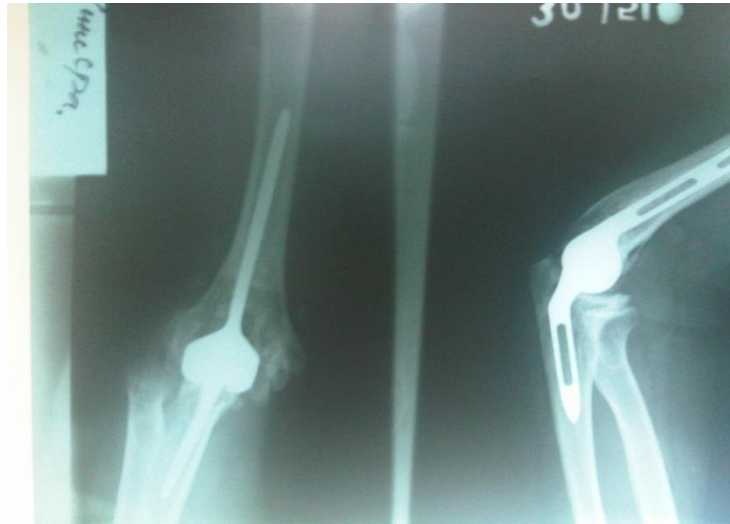

- After operation his Range of Movement increase to 95 degree of flexion and full extension.

### Case 2

Male, 45<sup>th</sup> years old

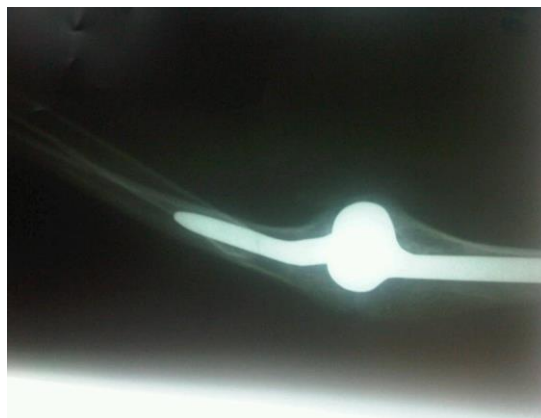- Has an Osteoarthritis of his right elbow.
- He couldn't move his elbow cause of elbow pain.
- Undergone Total Elbow Arthroplasty on February 2012
- After operation his range of movement increase , 0 – 100 degree flexion
- Painfree



### Case 3

Female, 64 years old

- Couldn't move her elbow cause of elbow pain
- She has contracture on her elbow
- She has an Osteoarthritis on her elbow
- Undergone Total Elbow Arthroplasty on March 2012

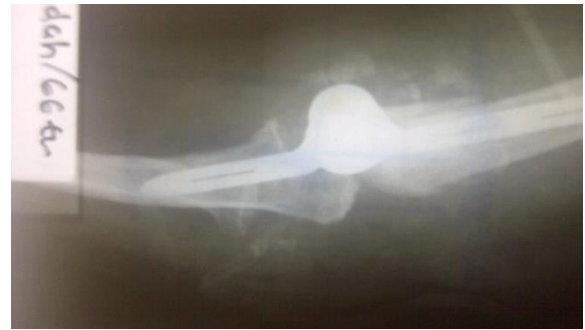
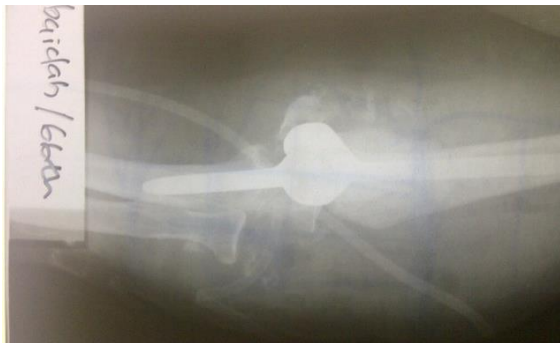
- After operation her Range of Movement increase from 30 degree to 100 degree flexion, with full extension.
- Triceps disruption following total elbow arthroplasty is a well recognized problem.

#### Case 4

Female, 66 years old

- Pain on her left elbow
- Contracture on her left elbow
- Couldn't move her left elbow
- The articular surface was breakdown
- Undergone Total Elbow Arthroplasty on April 2012.



- After operation her elbow Range of Movement increase from 15 degree to 85 degree, pain free
- Unfortunately the elbow is not stable , maybe due to the stem of the implant is to short.

#### Case 5

Female, 47 years old

- Deformity on her right elbow
- Couldn't move her elbow
- Her elbow fixed at 30 degree flexion
- Undergone Total Elbow Arthroplasty on June 2012
- After operation the result are not to good
- Her elbow range of motion only from 10 degree to 75 degree
- This condition maybe cause by condition of the implant, the implant is to short.

## **2. Discussion**

A posterior triceps-sparing approach, which preserves the continuity of the triceps, when possible, is typically used.

Postoperative therapist and patient need to respect the integrity of the triceps and posterior incision when performing both active and passive elbow flexion exercises and functional activities

## **3. Conclusion**

Despite the complications that can occur with total elbow arthroplasty, it has become a primary choice for the treatment of low-demand patients with complex fractures or advanced elbow arthritis. Semiconstrained total elbow arthroplasty is a useful option for patients with an ankylosed or a very stiff elbow and results in a considerable improvement of motion

## **4. References**

1. P. Mansat, Bonneville, M. Rgieres, M. Mansat et al, Results with a minimum, of 10 years follow-up of the Conrade/Morrey total elbow arthroplasty; Orthopaedics & Traumatology : Surgery & Research (2013), S337-S343
2. P. Mansat. N. Bonneville. M.Rongieres, et al; The role of total elbow arthroplasty in traumatology: Orthopaedics & Traumatology: Surgery & research 100 (2014) S293-S298
3. S. Joachim Sanchez. Total Elbow Arthroplasty, The Open Orthopaedics Journal, 2011,5, 115-123
4. Wheelless C.R. III, Total Elbow Arthroplasty in Wheelless Textbook of Orthopaedics, updated June 29, 2016
5. Pooley, J. Total elbow replacement – patient selection and perspectives. Orthopaedic Research and Reviews 2019:11 23-40
6. Dee R. Total replacement Arthroplasty of the elbow for rheumatoid arthritis. J Bone Joint Surg Br. 1972;54(1):88-95





7. Little CP, Carr AJ, Graham AJ, Total Elbow Arthroplasty: a systematic review of the literature in the English language until the end of 2003. *J Bone Joint Surg Br* 2005;87(4): 437-44
8. Cobb TK, Morrey BF, Total Elbow Arthroplasty as a primary treatment for distal humeral fractures in elderly patients. *J Bone Joint Surg Am* 1997;79:826-32
9. Gambirasio R, Riand N, Stern R, et al. Total elbow replacement for complex fractures of the distal humerus: an option for elderly patient. *J Bone Joint Surg Am*. 2001;83:974-8
10. Ray PS, Kakarlapudi K, Rajsekhar C, et al. Total Elbow arthroplasty as primary treatment for distal humeral fractures in elderly patients. *Injury* 2000; 31:687-92